



OSSIX[®] Plus

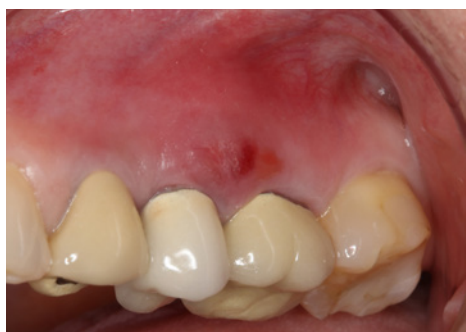Correction of Vertical Fracture
and Subsequent Infection

Dr. Matthew J Fien, DDS, FL, USA

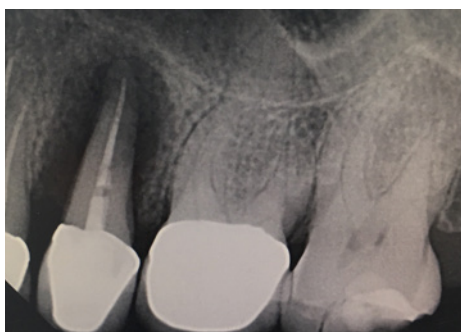Case background

46 year old female with a non-contributory medical history presented for evaluation and treatment of swelling in her upper left quadrant. Intra oral exam revealed moderate swelling and a buccal fistula 3 mm from gingival margin of tooth 13. The radiograph revealed severe bone loss as a result of fracture and subsequent infection of tooth 13. Following extraction and full thickness flap reflection, all granulomatous tissue was meticulously debrided from the defect. The defect was grafted with a freeze dried bone allograft and an OSSIX® Plus membrane was adapted to the buccal occlusal palatal line angle and secured with a periosteal biting stabilization suture.

Pre-op

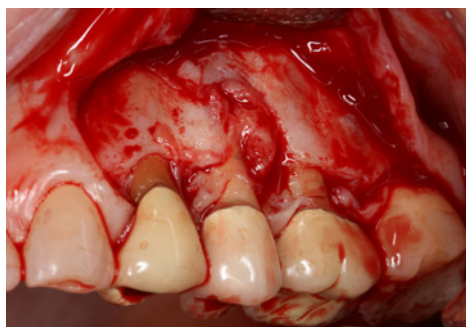


Pre-op Buccal view

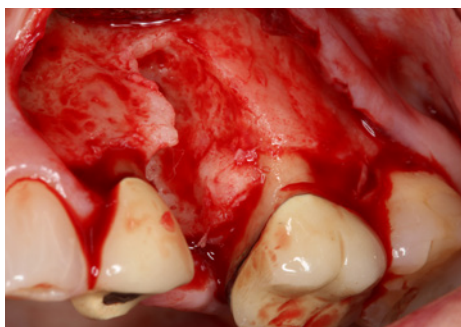

Pre-op X-ray

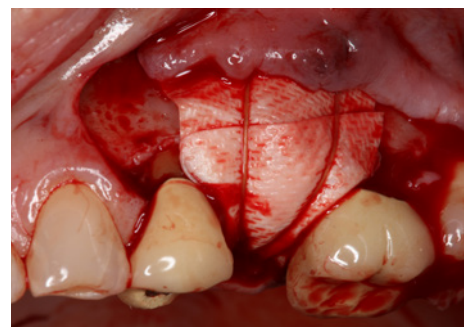
Procedure



Full thickness flap reflection

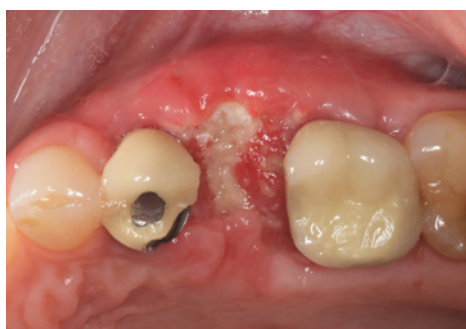


Extraction and degranulation

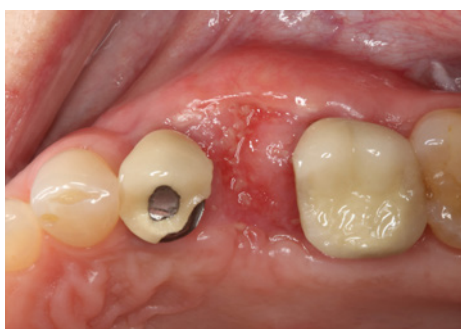


Membrane stabilization with resorbable suture

Post-op - Follow up 2-4 weeks



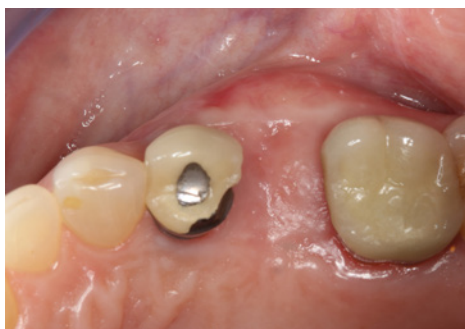Occlusal view of healing at 2 weeks post-op reveals soft tissue dehiscence at incision line but no signs of infection



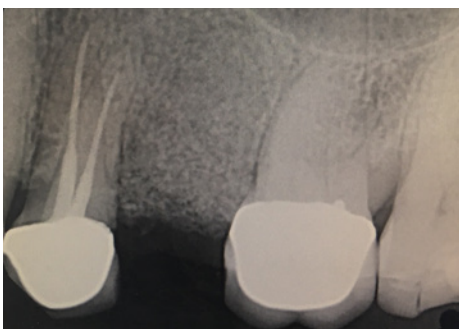Occlusal view at 4 weeks post-op reveals almost complete healing over graft/membrane complex

Please refer to OSSIX Plus IFU for the full information on indications and contraindications.

Post-op - Follow up at 4 months

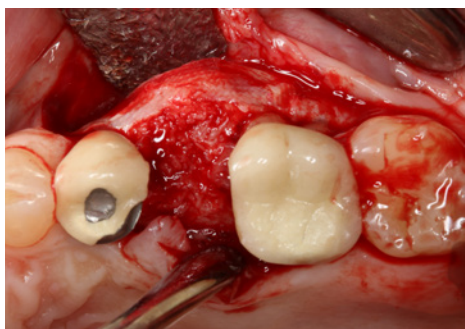


Full recovery after 4 months. Note significant increase in contours of ridge in the area of previous infection

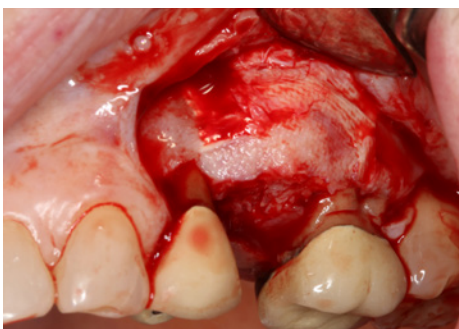


Radiograph at 4 months post-op reveals complete defect fill and good incorporation of bone graft. Note the maintenance of vertical height of alveolar ridge despite the presence of severe dehiscence defect at the time of extraction

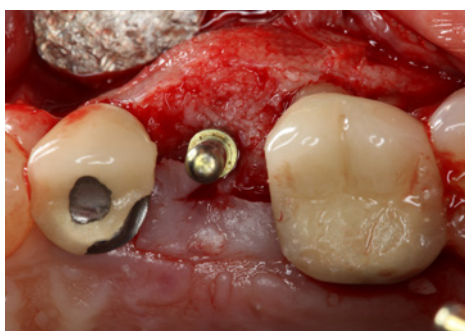Implant placement – at 5 months



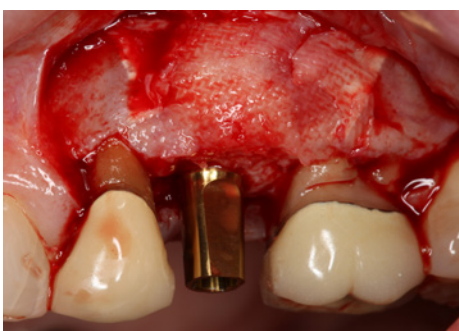
Occlusal view of regenerated ridge at the time of implant placement



Buccal view of regenerated ridge at the time of implant placement. Remnants of OSSIX Plus membrane can be seen protecting the healed ridge



Occlusal view at the time of implant placement following initial osteotomy preparation and placement of a guide pin. Note significant increase in ridge width beyond the confines of the alveolar housing



Buccal view following implant placement. Note imprinting of herring bone pattern in regenerated bone and re-establishment of the buccal occlusal line angle

Correction of Vertical Fracture and Subsequent Infection

OSSIX® Plus is the only ossifying Collagen Barrier Membrane
For Guided Bone Regeneration (GBR) & Guided Tissue
Regeneration (GTR) Procedures

OSSIX Plus is available in 3 sizes.

OSSIX Plus is currently available in countries on all continents including the USA, Europe, Argentina, Canada, Chile, Colombia, Dominican Republic, Hong Kong, India, Israel, Korea, Mexico, Russia, Singapore, and Taiwan.

datumdental



www.ossixdental.com